



**PATIENT**  
Parker Toney

**PRESENTING CLINICAL SIGNS**

History: Gallop heart rhythm. No clinical signs. No murmur noted.  
\*Sedated with Torbugesic and Midazolam.

**SPECIES**  
Feline

**ECHOCARDIOGRAM FINDINGS**

2D, m-mode, color flow and Doppler imaging is available.

**BREED**  
DSH

**Left ventricle:** The LV diameter is normal with adequate myocardial function. The LV wall dimensions are normal. There is mild fibrosis of the endocardium. The endocardium appears mildly remodeled. The papillary muscles appear hyperechoic and normal in dimension.

**SEX**

Male Neutered

**Left atrium:** The left atrium is normal. No obvious thrombi seen.

**Mitral valve:** The mitral valve is normal in structure and mobility. No obvious systolic anterior motion is seen. No MR.

**AGE**

8 years

**Aortic valve/aorta:** The aortic valve is normal in morphology and mobility. Normal aortic outflow velocity; laminar flow. No aortic insufficiency.

**Right ventricle:** Normal right ventricular diameter and morphology indicating no overt evidence of pulmonary arterial hypertension.

**Right atrium:** The right atrium is normal in dimension.

**WEIGHT**

16.5lbs

**Tricuspid valve:** The tricuspid valve appears normal with trace tricuspid regurgitation.

**Pulmonic valve/pulmonary artery:** The pulmonic valve is normal in morphology and mobility. No pulmonic insufficiency. Normal RVOT velocity; laminar flow.

**Pericardium/other:** No pericardial or pleural effusion noted. No obvious cardiac masses.

**Heart rhythm:** ECG reveals a sinus rhythm with an average HR of 210bpm.

**INTERPRETED BY**

Maggie Machen  
Lamy, DVM  
DACVIM (Cardiology)

**2-Dimensional Measurements**

Ao diam (cm)	0.94
LA diam (cm)	1.1
LA:Ao (Swe)	1.2
IVS thickness (cm)	0.50
LVID diastole (cm)	1.1
PW thickness (cm)	0.54
LVID systole (cm)	0.7
FS (%)	38

**Doppler Measurements**

PV Vmax (m/s)	0.8
AoV Vmax (m/s)	0.93
MR Vmax (m/s)	NA
TR Vmax (m/s)	NA
TR PG (mmHg)	NA

**IMAGING PERFORMED BY**

Pamela Harrigan,  
RDMS

**HOSPITAL NAME**

Wignall Animal  
Hospital

**INTERPRETATION OF THE FINDINGS**

Overtly normal cardiac structure and function are identified. Mild remodeling fibrosis of the left ventricular wall is noted, which is likely a normal age-related variant. No significant valve leaks are noted, and flow through the great vessels is normal in velocity. No significant pathology is appreciated to explain the gallop, this likely suggests this is a normal age-related finding due to diastolic stiffening.

**REFERRING VET**

Dr. Colella

Prognosis is open.

**INVOICE**

29633

**RECOMMENDATIONS**

- Given these findings, no medications are indicated.
- No cardiac contraindication for general anesthesia. Should fluid or steroid therapy be indicated in the future, any cat should be monitored for intolerance (changes in RR/RE).

**DATE**

3/16/23



**PATIENT** - Monitor at home for signs of cardiac compromise, including respiratory changes and/or signs of a blood clot event (paralysis, neurologic changes).  
 Parker Toney

**PLAN**  
 - Recommend recheck echocardiogram in 1 year to screen for any progressive issues.

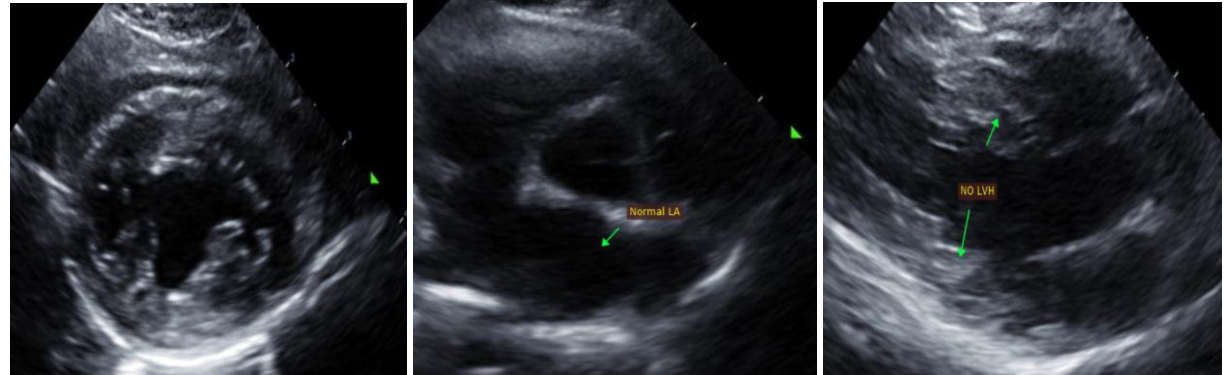
**SPECIES**  
 Feline

**IMAGES**

**BREED**  
 DSH

**SEX**  
 Male Neutered

**AGE**  
 8 years



**WEIGHT**  
 16.5lbs

The information and recommendations provided are based on the images presented by the referring veterinarian. No evaluation can be communicated regarding pathology that was not visible in the image/video clips provided.

**INTERPRETED BY**

Maggie Machen Lamy, DVM  
 DACVIM (Cardiology)

Thank you for this referral. This report was generated using transcription software, and minor dictation errors may be present. If the clinical or image interpretation does not parallel your findings or if I can be of any further assistance, please contact me.

**Maggie Machen Lamy, DVM**  
 Diplomate of the American College of Veterinary Internal Medicine (Cardiology)  
 info@sonopath.com

**IMAGING PERFORMED BY**

Pamela Harrigan, RDCS

**Echocardiogram performed by:** Pamela Harrigan, RDCS  
 Pet Animal Ultrasound Service ([4paus.com](http://4paus.com))

**HOSPITAL NAME**

Wignall Animal Hospital

**REFERRING VET**

Dr. Colella

**INVOICE**

29633

**DATE**

3/16/23